

Inguinal herniation of an ovarian dermoid in an adult with disorder of sex development and müllerian–renal anomalies: A clinical conundrum

Narayanaswamy Kavitha ^{1,*}, Potharaju Jayanthi ², Lavanya Palli ²¹ Postgraduate, Department of Obstetrics and Gynecology, Guntur Medical College and General Hospital, Guntur, Andhra Pradesh, India² Department of Obstetrics and Gynecology, Guntur Medical College and General Hospital Guntur, Andhra Pradesh, India

Received: 13 Feb 2026 Accepted: 25 April 2026

Abstract

Background: Mature cystic teratomas (dermoid cysts) are common benign ovarian tumors; however, their presentation within an inguinal hernia is exceedingly rare. When accompanied by features of a disorder of sex development (DSD) and coexisting Müllerian–renal anomalies, diagnostic evaluation becomes significantly more complex.

Case Presentation: We report a 30-year-old nulligravida with an eight-year history of primary infertility and a progressively enlarging left groin mass. Physical examination showed short stature, webbed neck, shield chest, and external genital findings consistent with a DSD, including a 3-cm phallus-like structure with a preputial hood. Imaging revealed a unicornuate uterus and a large adnexal cyst herniating into the inguinal canal. Computed Tomography (CT) urogram demonstrated a malrotated, non-functioning left kidney. During laparotomy and inguinal exploration, the hernia sac contained the left ovary, a broad-ligament cyst, and a rudimentary uterine horn. Histopathology confirmed a mature cystic teratoma. Postoperative recovery was uneventful, and the patient received multidisciplinary counseling.

Conclusion: This rare case highlights the need to consider underlying DSD and congenital Müllerian–renal anomalies when encountering inguinal adnexal herniation in individuals presenting with infertility or atypical phenotypic features. Accurate anatomical assessment and multidisciplinary management are essential for optimal care.

Keywords: Anomalies, Hernia, Ovary, Uterus

Introduction

The term “teratoma” was first introduced by Virchow, derived from the Greek word teraton, meaning “monster,” while Leblanc later used the term “dermoid cyst” to describe these lesions (1,2). Mature cystic teratomas arise from totipotent germ cells and represent one of the most common benign ovarian tumors encountered in reproductive-age individuals (3). Although typically located within the ovary and often presenting as slow-growing adnexal masses, they are frequently asymptomatic and may only become clinically evident when complicated by torsion, rupture, or secondary infection (4).

In rare situations, adnexal structures can herniate through the inguinal canal, an occurrence more

commonly described in pediatric populations than in adults. When such herniation coexists with features of a disorder of sex development (DSD) and Müllerian duct anomalies, the diagnostic and clinical complexity increases substantially.

The present report describes an unusual case in which a mature ovarian dermoid cyst constituted the content of an inguinal hernia in an adult patient with multiple congenital urogenital malformations. This case highlights the importance of considering underlying DSD and Müllerian–renal anomalies when evaluating atypical inguinal masses, particularly in individuals presenting with infertility or nonstandard phenotypic features.

*Correspondence author: Dr. Narayanaswamy Kavitha, ORCID ID: -0009-0008-3874-207, Email: kavitha.nrnswm@gmail.com



This work is licensed under a Creative Commons Attribution-NonCommercial 4.0 International License. Copyright © 2020 Iranian Caspian Journal of Reproductive Medicine, and Babol University of Medical Sciences.

Case report

A 30-year-old nulligravida presented with an eight-year history of primary infertility and a progressively enlarging swelling in the left groin. Her menstrual cycles had remained regular since menarche at 12 years of age. There was no significant family history of endocrine, genetic, or urogenital disorders. All required consents were obtained prior to the preparation of this case report.



Figure 1. Preoperative photograph showing the left inguinal swelling and external genital features.

On general physical examination, she had short stature, a webbed neck, and a shield-shaped chest, giving a Turner-like appearance. Secondary sexual characteristics were underdeveloped, with Tanner stage 2 breast development. Pubic hair was present, whereas axillary hair was absent. Local examination revealed a 7 × 10 cm irreducible, non-tender swelling in the left inguinal region with the consistency of a hernia, along with a 5 × 5 cm soft-tissue mass consistent with a perineal lipoma. The preoperative external findings, including the left inguinal swelling and a 3-cm phallus-like structure covered by a preputial hood, are shown in Figure 1.

Table 1. Investigations

| Test | Result | Reference range |
|----------------|------------|-------------------------|
| Testosterone | 0.93ng/ml | 0.1–0.75 ng/ml (Female) |
| FSH | 3.7 mIU/mL | Variable by cycle phase |
| CA-125 | 13.3 IU/mL | < 35 IU/mL |
| Serum Cortisol | 58.6 µg/dL | 5–23 µg/dL |
| Barr Body | Positive | - |

Laboratory investigations, including routine biochemical tests, were within normal limits. Hormonal evaluation (summarized in Table 1) did not reveal overt endocrine abnormalities. Peripheral blood smear and buccal smear both demonstrated a positive Barr body, suggesting the presence of at least one X chromosome.

Pelvic ultrasonography revealed a 12 × 6 cm pelvic cystic lesion extending into the left inguinal canal, suggestive of an adnexal mass herniating through the inguinal ring, along with a unicornuate uterus. Contrast-enhanced Computed Tomography (CT) urogram showed a malrotated, non-functioning left kidney with an absent ipsilateral ureteric orifice; the contralateral kidney was normal.

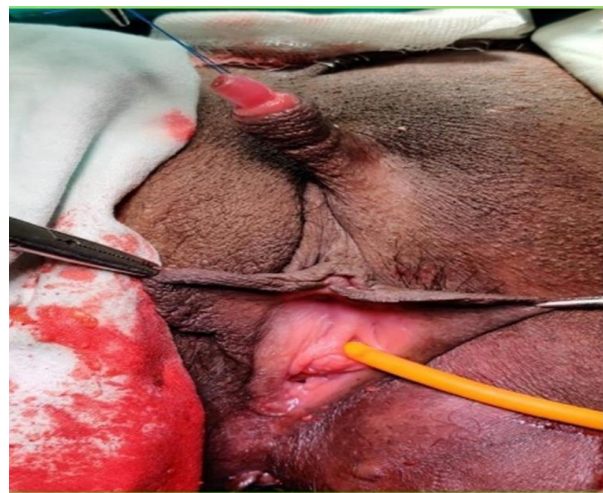

Figure 2. Intraoperative findings showing adnexal structures within the inguinal hernia sac.

The patient underwent exploratory laparotomy combined with inguinal exploration. Intraoperatively, the left ovary, a broad-ligament cyst and a rudimentary uterine horn were identified within the inguinal hernia sac, as illustrated in Figure 2. The adnexal structures were reduced, and mesh hernioplasty was performed. Excision of the phallus-like structure was undertaken following multidisciplinary discussion and informed consent, and the perineal lipoma was also removed. The immediate postoperative appearance is shown in Figure 3.

Histopathological examination of the excised ovarian cyst confirmed a mature cystic teratoma (dermoid cyst). The perineal mass was consistent with a benign lipoma. The intraoperative hernial sac contents,

including the rudimentary uterine horn and dermoid cyst, are shown in Figure 4. The postoperative course was uneventful, and the patient recovered well. She was subsequently referred for multidisciplinary counseling involving gynecology, endocrinology, urology, plastic surgery and psychology with emphasis on long-term follow-up, fertility potential, and psychosocial support.

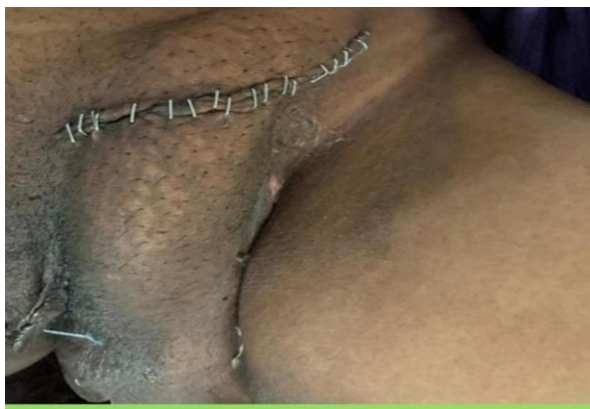


Figure 3. Postoperative appearance after hernia repair and excision of the phallus like structure.

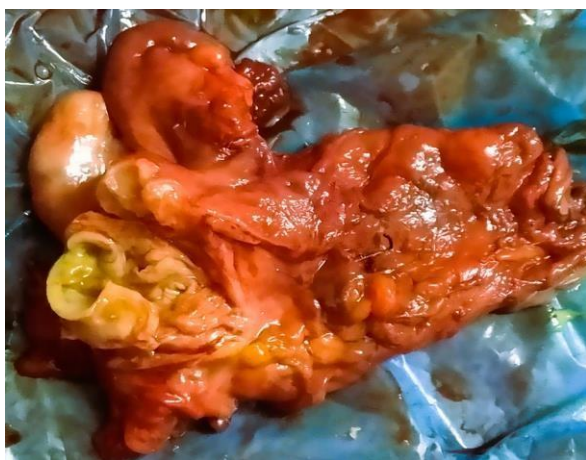

Figure 4. Intraoperative specimen from the inguinal hernia sac showing the rudimentary uterine horn and ovarian dermoid cyst.

Discussion

Mature cystic teratomas are the most common benign germ cell tumors of the ovary and are typically diagnosed in women of reproductive age. They are often asymptomatic and may remain clinically silent until they attain a considerable size or develop complications such as torsion, rupture, or infection (1,4). Inguinal herniation of adnexal structures, especially in association with a large dermoid cyst, is an unusual occurrence and is more frequently reported

in neonates and infants than in adult (5). In the present case, the inguinal hernia containing an ovarian dermoid in a 30-year-old woman represents a surgical and diagnostic rarity.

The diagnostic challenge in this patient extended beyond the unusual hernia content. The coexistence of Turner-like physical features (short stature, webbed neck, and shield chest), positive Barr body, regular menstruation, and the presence of internal female reproductive structures pointed toward a complex disorder of sex development (DSD) rather than a classical monosomy X (45, X) Turner syndrome. Classical Turner syndrome typically presents with streak gonads and primary amenorrhea; by contrast, our patient had ovarian tissue function sufficient to support regular menstrual cycles. This discrepancy suggests the possibility of chromosomal mosaicism or another form of DSD that could not be fully characterized in the absence of karyotyping.

The association of a unicornuate uterus with an ipsilateral non-functioning malrotated kidney in this case illustrates the intimate embryological relationship between the Müllerian (paramesonephric) ducts and the mesonephric system. Disturbances during organogenesis may result in concurrent Müllerian and renal anomalies, as described in various classifications of female genital tract malformations (6). While Mayer-Rokitansky-Küster-Hausler (MRKH) syndrome classically presents with uterovaginal agenesis and normal ovaries, the constellation of findings in our patient is better understood as a complex, unclassified Müllerian anomaly occurring in the context of DSD, rather than a typical MRKH or isolated Turner phenotype.

The presence of a phallus-like external genital structure in an individual with internal female reproductive organs reinforces the importance of using anatomically descriptive, non-stigmatizing terminology in the context of DSD. Traditional terms such as “ambiguous genitalia” and “micropenis” may be imprecise and potentially stigmatizing. Instead, neutral descriptions focusing on size, morphology, and location of structures are now preferred in clinical and academic communication. A comprehensive evaluation including chromosomal analysis, detailed hormonal profiling, and molecular studies is ideal for accurate classification of DSD; however, such investigations were not available in this case and represent a key limitation of the report.

From a surgical perspective, recognition of adnexal herniation is essential, as delay or misdiagnosis can

lead to complications such as torsion and subsequent compromise of ovarian function or loss of reproductive potential. Preoperative imaging, particularly ultrasonography and CT, played a crucial role in identifying the herniated adnexa and associated renal anomaly in this patient. Intraoperatively, reduction of the adnexal structures, excision of the dermoid cyst, and repair of the inguinal defect were successfully performed, preserving as much normal tissue as possible.

This case underscores the need for a high index of suspicion for underlying congenital urogenital anomalies and DSD in individuals who present with inguinal hernia containing pelvic organs, particularly in the presence of infertility or atypical phenotypic features. It also highlights the importance of multidisciplinary management, encompassing gynecology, general surgery, urology, endocrinology, pathology, plastic surgery, and psychological support, to address the complex medical, reproductive, and psychosocial issues involved.

In summary, inguinal herniation of an ovarian dermoid in an adult with features of DSD and coexisting Müllerian–renal anomalies is exceptionally rare. Careful clinical assessment, appropriate imaging, and coordinated multidisciplinary care are essential for optimal diagnosis, surgical management, and long-term follow-up in such complex cases.

Conclusion

This rare case of an ovarian mature cystic teratoma presenting as inguinal hernia content in an adult with features of a disorder of sex development and associated Müllerian–renal anomalies illustrates the broad phenotypic spectrum and diagnostic complexity of DSD. Clinicians should maintain a high index of suspicion for underlying congenital urogenital anomalies when evaluating inguinal hernias in individuals with infertility or atypical phenotypic features. Comprehensive anatomical assessment and multidisciplinary management are crucial to optimize surgical outcomes, preserve reproductive potential when feasible, and provide appropriate psychosocial support.

Acknowledgements

The authors extend their sincere appreciation to the faculty and staff of the Departments of Obstetrics and Gynecology, General Surgery, Plastic Surgery, Urology, and Pathology at Guntur Medical College for

their valuable support in the diagnostic evaluation and multidisciplinary management of this patient.

Conflicts of Interest

The authors have no conflicts of interest to declare.

References

1. Damjanov I, Andrews PW. Teratomas produced from human pluripotent stem cells xenografted into immunodeficient mice - a histopathology atlas. *Int J Dev Biol.* 2016;60(10-11-12):337-419. doi: 10.1387/ijdb.160274id. PMID: 28000905; PMCID: PMC5338735.
2. Chang CF, Lin CK. A case of recurrent, bilateral ovarian mature teratoma in a young woman. *BMC Womens Health.* 2014 Apr 13;14:57. doi: 10.1186/1472-6874-14-57. PMID: 24726009; PMCID: PMC3996130.
3. Cleveland Clinic. Ovarian dermoid cyst: causes, symptoms & treatment [Internet]. Cleveland (OH): Cleveland Clinic; c2026 [updated 2022 Aug 4; cited 2026 Feb 8]. Available from: <https://my.clevelandclinic.org/health/diseases/23931-ovarian-dermoid-cyst>
4. Comerci JT Jr, Licciardi F, Bergh PA, Gregori C, Breen JL. Mature cystic teratoma: a clinicopathologic evaluation of 517 cases and review of the literature. *Obstet Gynecol.* 1994;84(1):22-28.
5. Karadeniz Cerit K, Ergelen R, Colak E, Dagli TE. Inguinal hernia containing uterus, fallopian tube, and ovary in a premature newborn. *Case Rep Pediatr.* 2015;2015:807309. doi: 10.1155/2015/807309.
6. Acién P, Acién MI. The history of female genital tract malformation classifications and proposal of an updated system. *Hum Reprod Update.* 2011 Sep-Oct;17(5):693-705. doi: 10.1093/humupd/dmr021. Epub 2011 Jul 4. PMID: 21727142.